

**Manuscript type:** Case Report

**DOI:** 10.5152/TurkThoracJ.2018.18015

**Title:** Rare Lung Tumors of Alveolar Adenoma: Four Case Reports

**Short title:** Alveolar Adenoma

**Authors:** Murat Kavas, Akın Öztürk, Onur Derdiyok, Cansel Atinkaya, Şenol Ürek, Abdurrahman Yılmaz, Ayşe Ersev, İrfan Yalçinkaya

**Intutions:** University of Health Sciences Sureyyapasa Chest Diseases and Thoracic Surgery Training and Research Hospital Department of Thoracic Surgery, İstanbul, Turkey

**Corresponding Address:** Cansel Atinkaya, University of Health Sciences Sureyyapasa Chest Diseases and Thoracic Surgery Training and Research Hospital Department of Thoracic Surgery, İstanbul, Turkey

**E-mail:** [catinkaya@gmail.com](mailto:catinkaya@gmail.com)

**Received:** 20.09.2018

**Accepted:** 03.04.2018

**Cite this article as:** Kavas M, Öztürk A, Derdiyok O, et al. Rare Lung Tumors of Alveolar Adenoma: Four Case Reports. Turk Thorac J 2018. DOI: 10.5152/TurkThoracJ.2018.18015

## **Abstract**

Alveolar adenoma is one of the rarely seen benign tumors of the lung, to date, one or two series have been reported. In this study, four rare alveolar adenoma cases were presented, thereby contributing to the existing scarce data.

**KEYWORDS:** Thoracic surgery, lung pathology

This article has been accepted for publication and undergone full peer review but has not been through the copyediting, typesetting, pagination and proofreading process, which may lead to differences between this version and the Version of Record. Please cite this article as: Derdiyok O, Kavas M, Öztürk A, et al. Rare Lung Tumors of Alveolar Adenoma: Four Case Reports. Turk Thorac J 2018. DOI: 10.5152/TurkThoracJ.2018.18015

©Copyright 2018 by Turkish Thoracic Society - Available online at [www.turkthoracj.org](http://www.turkthoracj.org)

## INTRODUCTION

Alveolar adenoma is one of the rare benign tumors of the lung. It was first described in a six case studies by Yousem and Hochholzer in 1986 [1]. Burke et al. [2] evaluated the clinical and pathological findings of alveolar adenomas with a 17 maturation series. It is usually found in middle-aged women and shows asymptomatic findings in chest radiographs. Overall less than 1% of all lung tumors have been reported to be detected [1-3]. Here, we present four cases (one male and three females) of alveolar adenoma. The patients provided written informed consent for publication.

## CASE PRESENTATIONS

### Case 1

A 36-year-old male patient presented to our clinic with a complaint of chest pain. There was no obvious feature in the physical examination and in the patient's history. The blood pressure was 120/80 mmHg, pulse rate was 95/min, body temperature was 36.5°C, and respiration rate was 26/min. The laboratory parameters are within normal limits. A thoracic computed tomography (CT) scan revealed a 26-mm nodule without calcification in the left lower lobe (Figure 1). A fiberoptic bronchoscopy (FOB) examination showed no pathology. A positron emission CT (PET-CT) revealed a 26-mm nodule (SUV-max 2,8) in the left lower lobe of the lung. A diagnosis was not made despite transthoracic fine needle aspiration. Agglutinin tests for hydatid cysts were negative. The forced vital capacity) in the pulmonary function test was 2.8 L, 98%, forced expiratory volume in 1 s was 2.4 L, 93%. The lesion was reported as benign in the thoracotomy-derived frozen section. The pathologic diagnosis was alveolar adenoma (Figure 2). No pathology was found in the 34-month follow-up of the patient.

### Case 2

A 51-year-old woman was admitted to our clinic with shortness of breath. A posterior-anterior-posterior chest X-ray showed uniformly increased density of approximately 2 cm in the right hemithorax subregions. In the thoracic CT, a solitary pulmonary nodule with a diameter of 1.8 cm was localized paravertebrally in the posterior segment of the right upper lobe (Figure 3). The bronchial system was routinely evaluated in the FOB examination. Thoracotomy was performed due to a family history of hydatid cyst. When the lesion was diagnosed as frozen cutaneous benign, thoracotomy was performed through wedge resection. The pathological diagnosis was alveolar adenoma. No pathology was found in the 15-year follow-up of the patient.

### Case 3

A 38-year-old female patient presented with thoracic hemoptysis and pain. Thoracic CT revealed a 1.3 cm diameter pulmonary nodule in the anterior segment of the right upper lobe. No pathology was detected in the FOB. Thoracotomy was performed because of hemoptysis. The lesion was diagnosed as

This article has been accepted for publication and undergone full peer review but has not been through the copyediting, typesetting, pagination and proofreading process, which may lead to differences between this version and the Version of Record. Please cite this article as: Derdiyok O, Kavas M, Öztürk A, et al. Rare Lung Tumors of Alveolar Adenoma: Four Case Reports. Turk Thorac J 2018. DOI: 10.5152/TurkThoracJ.2018.18015

frozen cutaneous and benign, and thoracotomy was performed with wedge resection. The pathological diagnosis was alveolar adenoma. No pathology was detected in the 10-year follow-up of the patient.

#### **Case 4**

A 59-year-old female patient complained of left shoulder pain, and a thoracic CT scan revealed a 2 cm pulmonary nodule in the left lower lobe. There was no endobronchial lesion in an FOB examination. The lesion was removed through thoracotomy wedge resection after the frozen section was reported as benign. The pathological diagnosis was alveolar adenoma. No pathology was detected in the 8-year follow-up of the patient. The patient provided written informed consent for publication.

#### **DISCUSSION**

Alveolar adenoma is usually detected by chest X-rays taken by chance in middle-aged women. Only one case was male in our series. Clinically, it is usually asymptomatic. In rare cases, symptoms of shortness of breath, chest pain, and persistent cough have been reported. Alveolar adenoma is seen in both genders, but it is rare in males [4-6]. In our series, symptoms were as shortness of breath, chest pain, and hemoptysis. It is usually determined radiologically as a solitary pulmonary nodule. The differential diagnosis of alveolar adenoma cases should be accepted as papillary adenoma, bronchoalveolar carcinoma, sclerosing hemangioma, and hamartoma [5-7]. Cystic hydatid was considered in the differential diagnosis because one patient had a family history. Microscopic invasion, which is generally considered to be a benign neoplasm but is thought to be malignant in the literature, has not been identified in the literature [8]. In our cases, the diagnosis was made by the wedge done with thoracotomy. Because the lesion was close to the center of the parenchyma, video thoracoscopy was not preferred. The root is not fully illuminated and does not have a malignant potential. After surgery, Burke et al. a prognosis of 13 years was observed in five cases and no recurrence or metastasis was reported [2,3].

After 15 years of follow-up, recurrence and metastasis did not develop in our study. In the immunohistochemical analysis, alveolar adenomatous tumor sections usually include cytokeratin, thyroid transcription factor-1 (TTF-1), epithelial membrane antigen for epithelial cells, glycoprotein cells associated with pulmonary surfactant, and interstitial cell types. Furthermore, partial positivity for CD34 and smooth muscle actin was noted. The epithelial component was immunohistochemically positive for TTF-1, surfactant apoprotein, napsine, and carcinoembryonic antigen, and the tumor suppressor may appear negative for p53 [9].

Therefore, alveolar adenomas should be considered in the differential diagnosis of solitary pulmonary nodules from rare tumors of the lung. Surgical resection should be considered for diagnosis and treatment.

This article has been accepted for publication and undergone full peer review but has not been through the copyediting, typesetting, pagination and proofreading process, which may lead to differences between this version and the Version of Record. Please cite this article as: Derdiyok O, Kavas M, Öztürk A, et al. Rare Lung Tumors of Alveolar Adenoma: Four Case Reports. Turk Thorac J 2018. DOI: 10.5152/TurkThoracJ.2018.18015

**Informed Consent:** Written informed consent was obtained from patients who participated in this study.

**Peer-review:** Externally peer-reviewed.

**Author Contributions:** Concept - İ.S.K.; Design - T.Ç., İ.S.K.; Supervision - T.Ç., İ.S.K.; Resources - T.Ç., İ.S.K.; Materials - T.Ç.; Data Collection and/or Processing - T.Ç.; Analysis and/or Interpretation - T.Ç., İ.S.K., Y.B.Ü., E.Ü., H.Ş.; Literature Search - T.Ç., İ.S.K., Y.B.Ü.; Writing Manuscript - T.Ç., İ.S.K.; Critical Review - T.Ç., İ.S.K., Y.B.Ü., E.Ü., H.Ş.; Other - T.Ç., İ.S.K., Y.B.Ü.

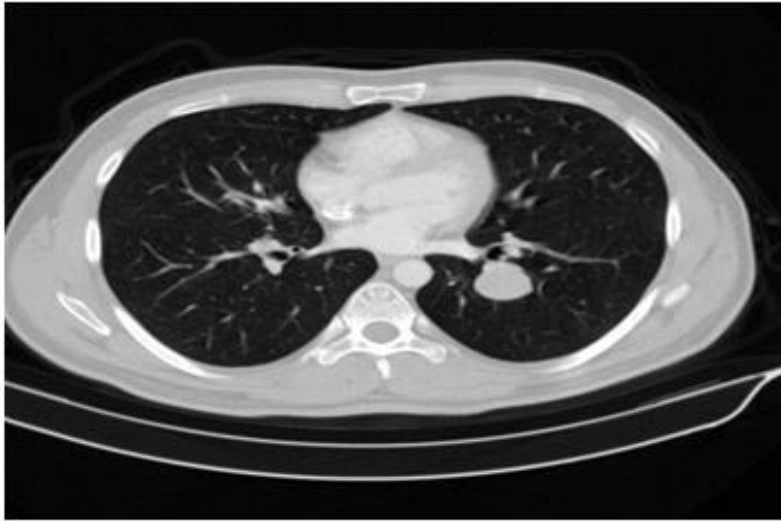**Conflict of Interest:** The authors have no conflicts of interest to declare.

**Financial Disclosure:** The authors declared that this study has received no financial support.

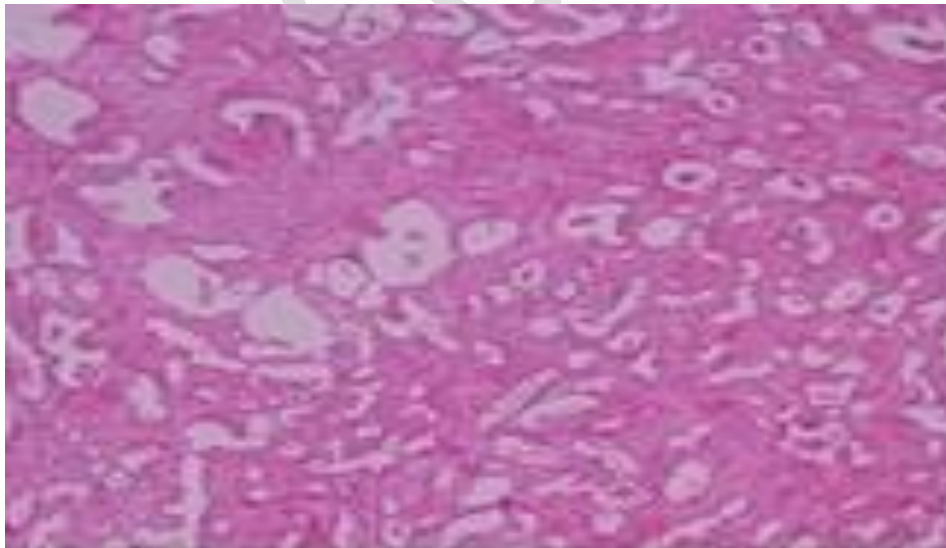
## REFERENCES

- [1] Yousem SA, Hochholzer L (1986). Alveolar adenoma. *Hum Pathol*, 17:1066-1071.
- [2] Burke LM, Rush WI, Khor A, et al: (1999). Alveolar adenoma: a histochemical. Immunohistochemical and ultrastructural analysis of 17 cases. *Hum Pathol*, 30:158-167.
- [3] Yilmaz A, Bayramgurler B, Aksoy F, (2002). Alveolar adenoma: a rare benign tumor of the lung. *Tuberkuloz ve Toraks Dergisi*; 50: 78–80.
- [4] Al-Hilli F (1987). Lymphangioma (or alveolar adenoma?) of the lung. *Histopathology*, 11, 970-980.
- [5] Fujimoto K, Muller NL, Sadohara J, Harada H, Hayashi A, Hayabuchi N (2002). Alveolar adenoma of the lung: computed tomography and magnetic resonance imaging findings. *J Thorac Imaging*, 17(2), 163-166.
- [6] Menet E, Etchand-Laclau K, Corbi P, (1999). Alveolar adenoma: a rare peripheral pulmonary tumor. *Ann Pathol*, 19, 325-328.
- [7] Panagiotou I, Kostikas K, Sampaziotis D, (2012). Alveolar adenoma: an extremely rare innocent coin lesion. *Interact Cardiovasc Thorac Surg*, 14, 335–337.
- [8] Mori M, Chiba R, Tezuka F, Kaji M, Kobubo T, (1996). Papillary adenoma of type II pneumocystis might have malignant potential. *Virchows Arch*, 428(3), 195-200.
- [9] X Zhang, Y Bai, X Wang, K Huang, (2017) Alveolar adenoma with the round-shaped

This article has been accepted for publication and undergone full peer review but has not been through the copyediting, typesetting, pagination and proofreading process, which may lead to differences between this version and the Version of Record. Please cite this article as: Derdiyok O, Kavas M, Öztürk A, et al. Rare Lung Tumors of Alveolar Adenoma: Four Case Reports. *Turk Thorac J* 2018. DOI: 10.5152/TurkThoracJ.2018.18015

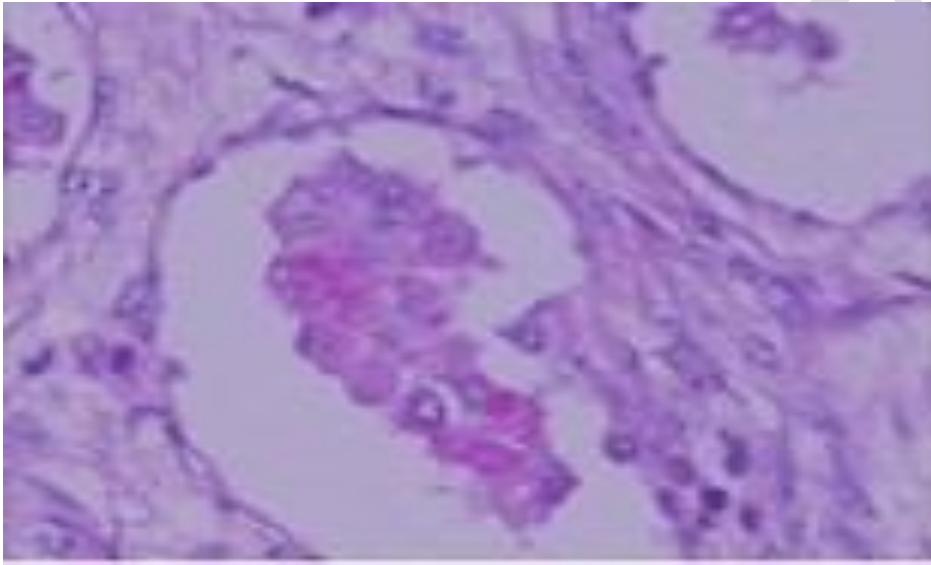


**Figure 1.** Case 1 - CT was performed on the left lower lobe with a smoothly defined, 26 mm sized nodule without calcification



This article has been accepted for publication and undergone full peer review but has not been through the copyediting, typesetting, pagination and proofreading process, which may lead to differences between this version and the Version of Record. Please cite this article as: Derdiyok O, Kavas M, Öztürk A, et al. Rare Lung Tumors of Alveolar Adenoma: Four Case Reports. Turk Thorac J 2018. DOI: 10.5152/TurkThoracJ.2018.18015

A

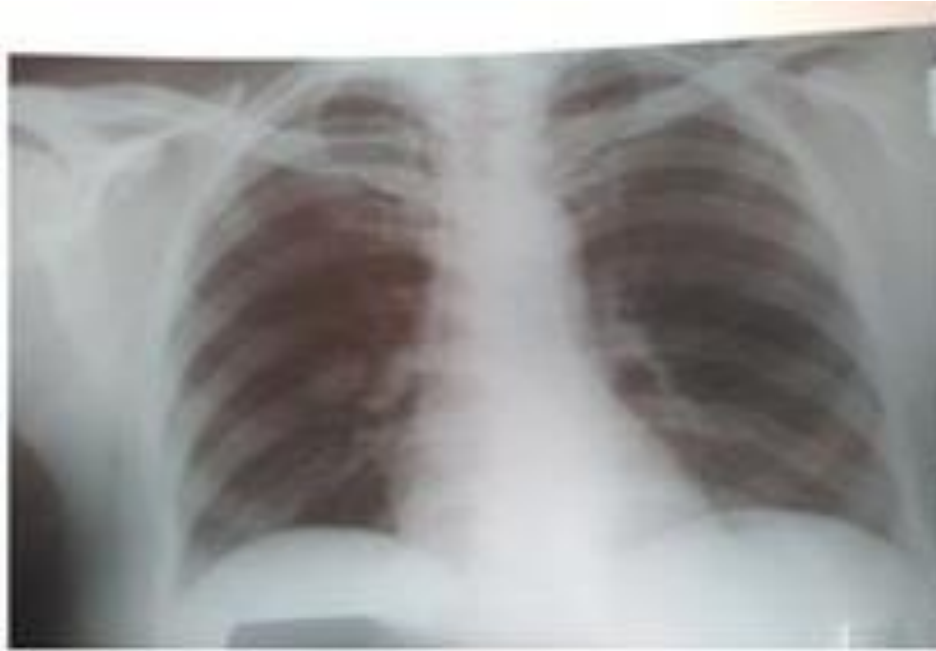

B

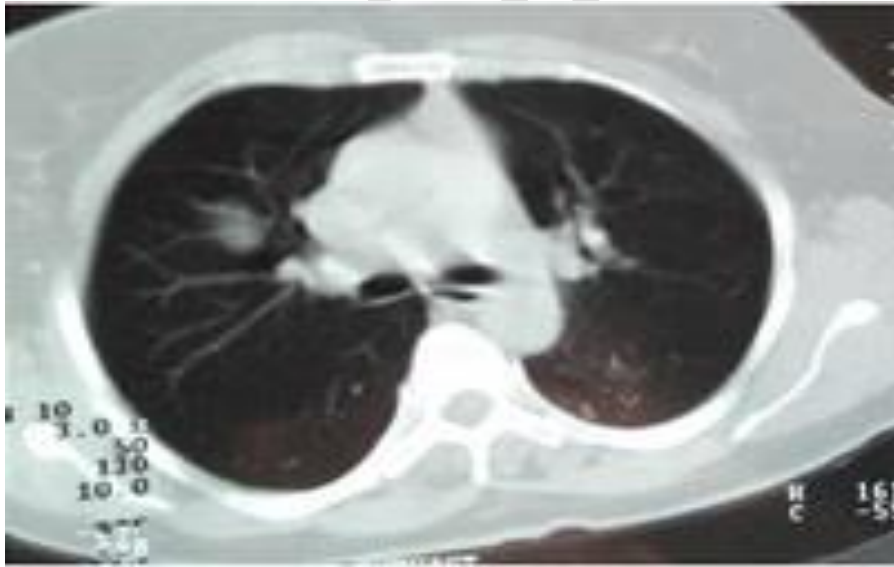
**Figure 2. a, b.** (a) Histopathological picture: Pleomorphic adenoma (hematoxylin and eosin stain, 100X) consisting of fibrous background placental epithelium elements with no nuclear or cellular atypical findings (b) lumen, periodic acid schiff (PAS) + eosinophilic secretions (PAS, 400X)

This article has been accepted for publication and undergone full peer review but has not been through the copyediting, typesetting, pagination and proofreading process, which may lead to differences between this version and the Version of Record. Please cite this article as: Derdiyok O, Kavas M, Öztürk A, et al. Rare Lung Tumors of Alveolar Adenoma: Four Case Reports. Turk Thorac J 2018. DOI: 10.5152/TurkThoracJ.2018.18015

©Copyright 2018 by Turkish Thoracic Society - Available online at [www.turkthoracj.org](http://www.turkthoracj.org)



A



B

This article has been accepted for publication and undergone full peer review but has not been through the copyediting, typesetting, pagination and proofreading process, which may lead to differences between this version and the Version of Record. Please cite this article as: Derdiyok O, Kavas M, Öztürk A, et al. Rare Lung Tumors of Alveolar Adenoma: Four Case Reports. Turk Thorac J 2018. DOI: 10.5152/TurkThoracJ.2018.18015

**Figure 3. a, b.** Case 2. (a) Rare limited density increase of about 2 cm in the right hemithorax in the lower zone of the posterioranterior lungs (b) Thoracic CT revealed a solitary pulmonary nodule with 1.8 cm in diameter localized in the right upper lobe posterior segment

UNCORRECTED

This article has been accepted for publication and undergone full peer review but has not been through the copyediting, typesetting, pagination and proofreading process, which may lead to differences between this version and the Version of Record. Please cite this article as: Derdiyok O, Kavas M, Öztürk A, et al. Rare Lung Tumors of Alveolar Adenoma: Four Case Reports. Turk Thorac J 2018. DOI: 10.5152/TurkThoracJ.2018.18015

©Copyright 2018 by Turkish Thoracic Society - Available online at [www.turkthoracj.org](http://www.turkthoracj.org)